

# 症例集

CPAC  2023

COMPLEX PERIPHERAL ANGIOPLASTY CONFERENCE 2023

11.24 FRI

CPAC  2023



**Case 8**    **70's male**

**Target Lesion: Lt. SFA**

**Diagnosis: LEAD, AP**

**ABI: R=0.89, L=0.73**

**Rutherford: 2**

**Prior intervention:**

**2022.12 PCI Stent**

**(LMT-LAD, prox. LCX)**

**2023.01 PCI POBA (dis. RCA)**

**2023.09 EVT POBA (Rt. SFA, ATA)**

**Risk Factor:**

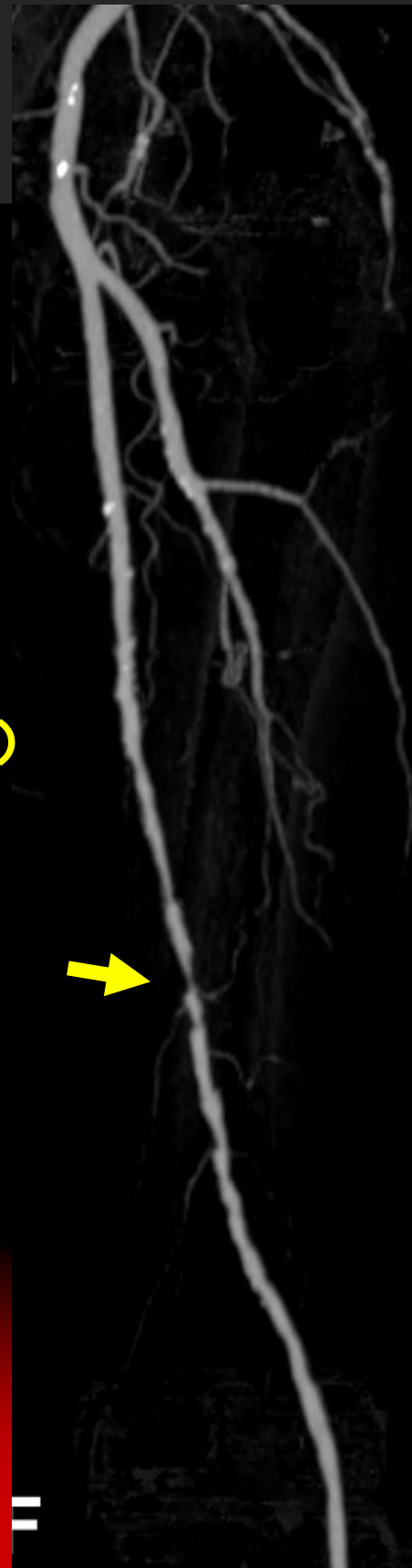
**DM, DL, past smoking**

**eGFR: 95.4**

**Angio Findings: 2023.06**

**Rt: SFA 90%**

**Lt: SFA 90%**





**Case 2** 70's female

Target Lesion: **Rt. CIA calcification**

Diagnosis: **LEAD, AP**

ABI: **R=0.62, L=1.17**

Rutherford: **3**

Prior intervention:

**2008-2023 PCI X 9**

**(RCA, LCX, LAD)**

**2023.09 LAAC**

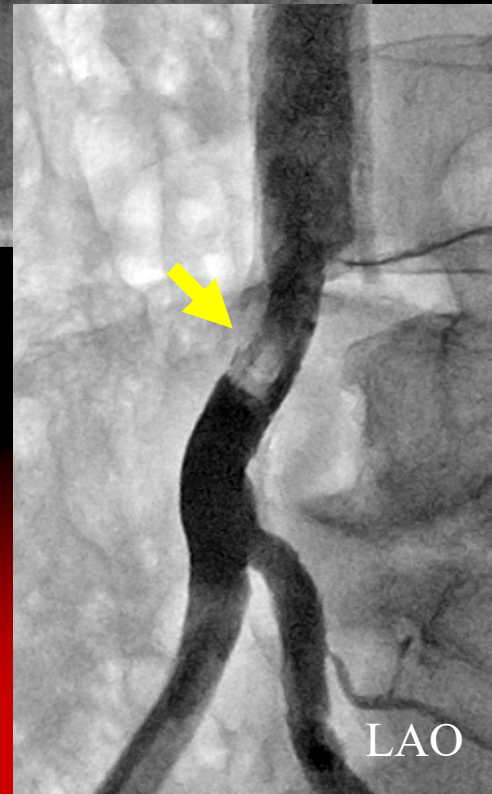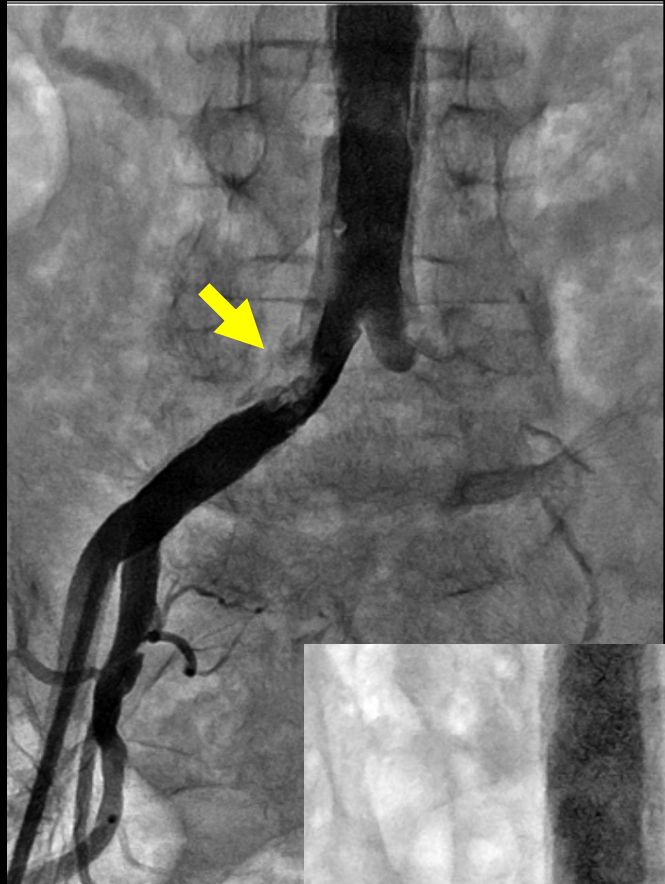Risk Factor:

**DM, HT, DL**

eGFR: **93.1**

Angio Findings: **2023.03**

Rt: **CIA 90%**





**Case 3**    **60's male**

**Target Lesion: Rt. SFA CTO**

**Diagnosis: LEAD**

**ABI: R=0.72, L=1.03**

**Rutherford: 3**

**Prior intervention:**

**2022.11 EVT DCB  
(Lt. SFA CTO)**

**Risk Factor:**

**HT, DL**

**eGFR: 52.6**

**Latest CT Findings: 2022.10**

**Rt: SFA 100%**

**Lt: SFA 100% → 25%(DCB)**





**Case 4**    **50's male**

**Target Lesion: Rt. CIA CTO**

**Diagnosis: LEAD**

**ABI: R=0.45, L=1.18**

**Rutherford: 3**

**Prior intervention:**

**none**

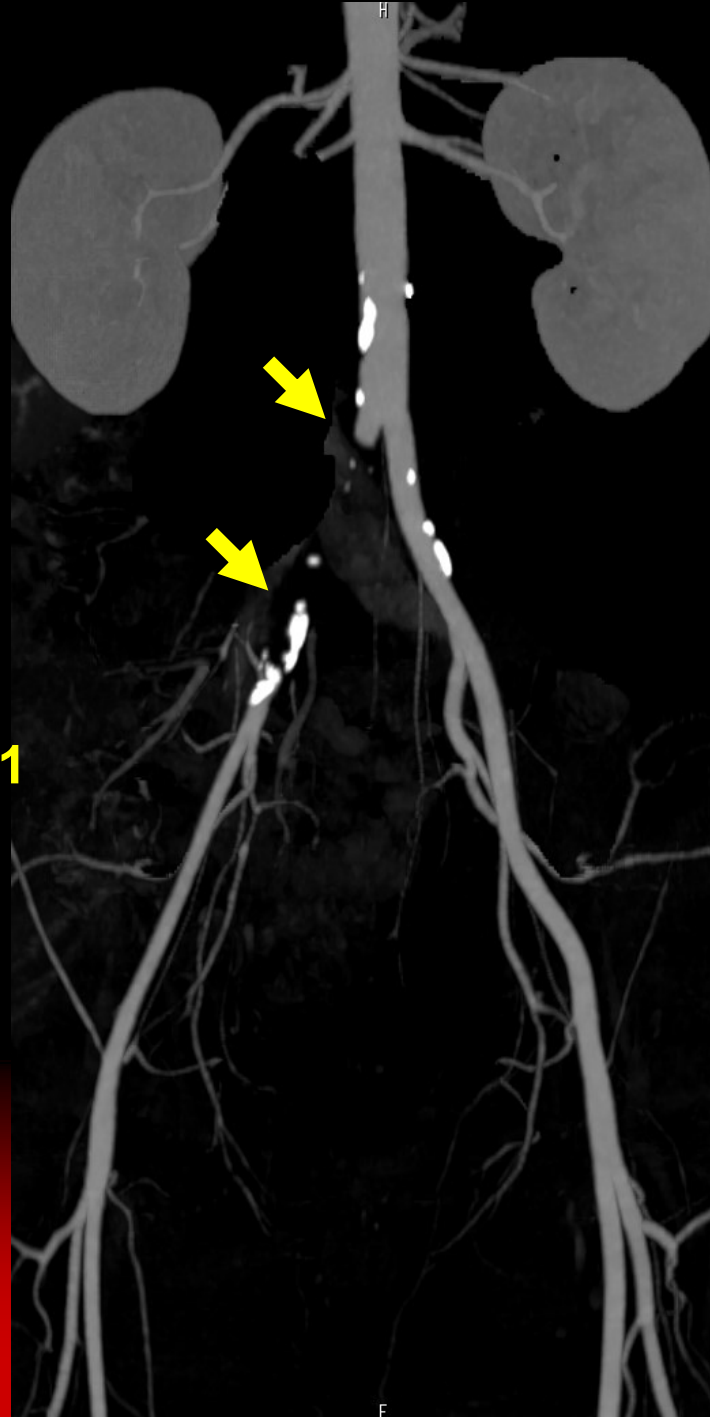
**Risk Factor:**

**HT**

**eGFR: 68.0**

**Latest CT Findings: 2023.11**

**Rt: CIA 100%**



11.25 SAT

CPAC  2023



**Case 5**    **70's male**

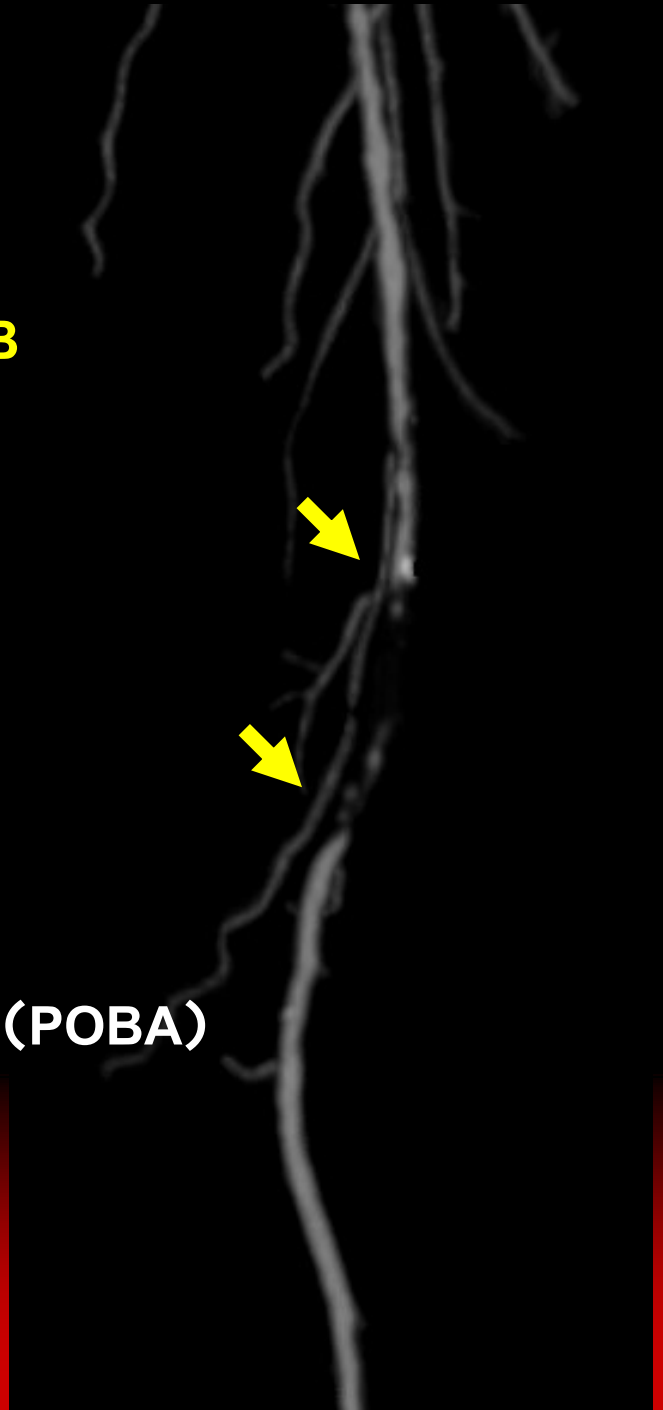
**Target Lesion: Rt. SFA CTO**

**Diagnosis: LEAD**  
**ABI: R=0.61, L=0.46**  
**Rutherford: 2**

**Prior intervention:**  
**2023.01 EVT Stent & DCB**  
**(Lt. EIA & SFA)**  
**2023.11 EVT POBA**  
**(Lt. EIA ISR)**

**Risk Factor:**  
**DM, HT, Current smoking**  
**eGFR: 79.0**

**Latest CT Findings: 2023.10**  
**Rt : SFA 100%**  
**Lt : EIA 90% (ISR) → 25% (POBA)**





**Case 6**    **70's female**

**Target Lesion: Lt. SFA CTO**

**Diagnosis: LEAD**

**ABI: R=0.69, L=0.44**

**Rutherford: 2**

**Prior intervention:**

**2021.03 EVT Stent & DCB  
(Rt. CIA-EIA & SFA)**

**Risk Factor:**

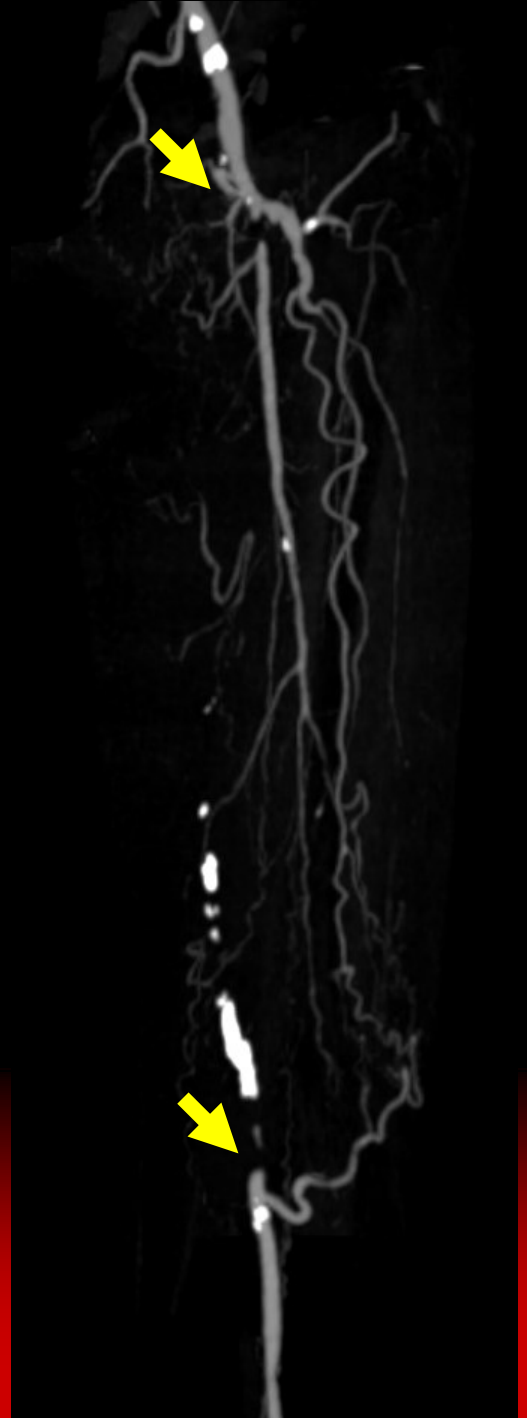
**HT, DL, Current smoking**

**eGFR: 56.1**

**Latest CT Findings: 2023.04**

**Rt: SFA 90%**

**Lt: SFA 100%**





**Case 7**    **70's female**

**Target Lesion: Lt. SFA CTO**

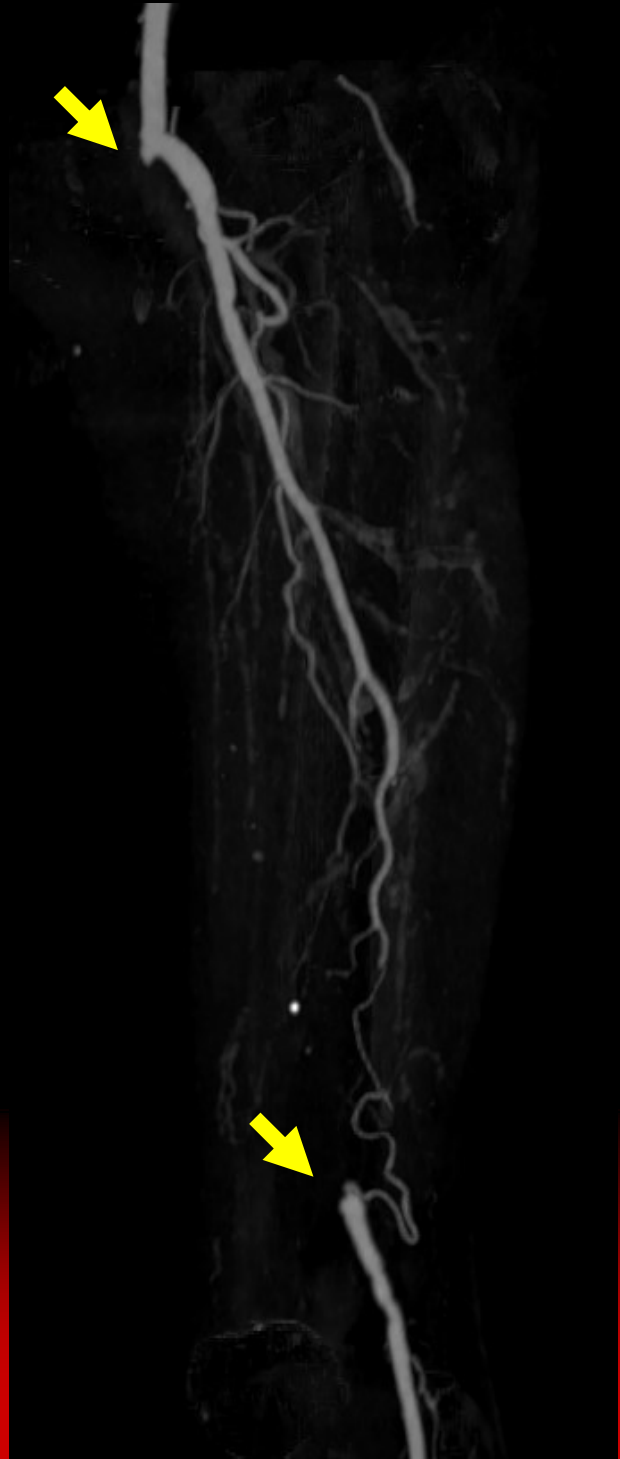
**Diagnosis: LEAD**  
**ABI: R=0.99, L=0.72**  
**Rutherford: 2**

**Prior intervention:**  
**none**

**Risk Factor:**  
**HT**

**eGFR: 68.7**

**Angio Findings: 2023.11**  
**Rt: SFA 90%**  
**Lt: SFA 100%**





**Case 10**    **70's female**

Target Lesion: **Rt. SFA CTO**

Diagnosis: **LEAD**

ABI: **R=0.54, L=0.92**

Rutherford: **2**

Prior intervention:

**2023.05 EVT Stent  
(Rt. EIA & SFA)**

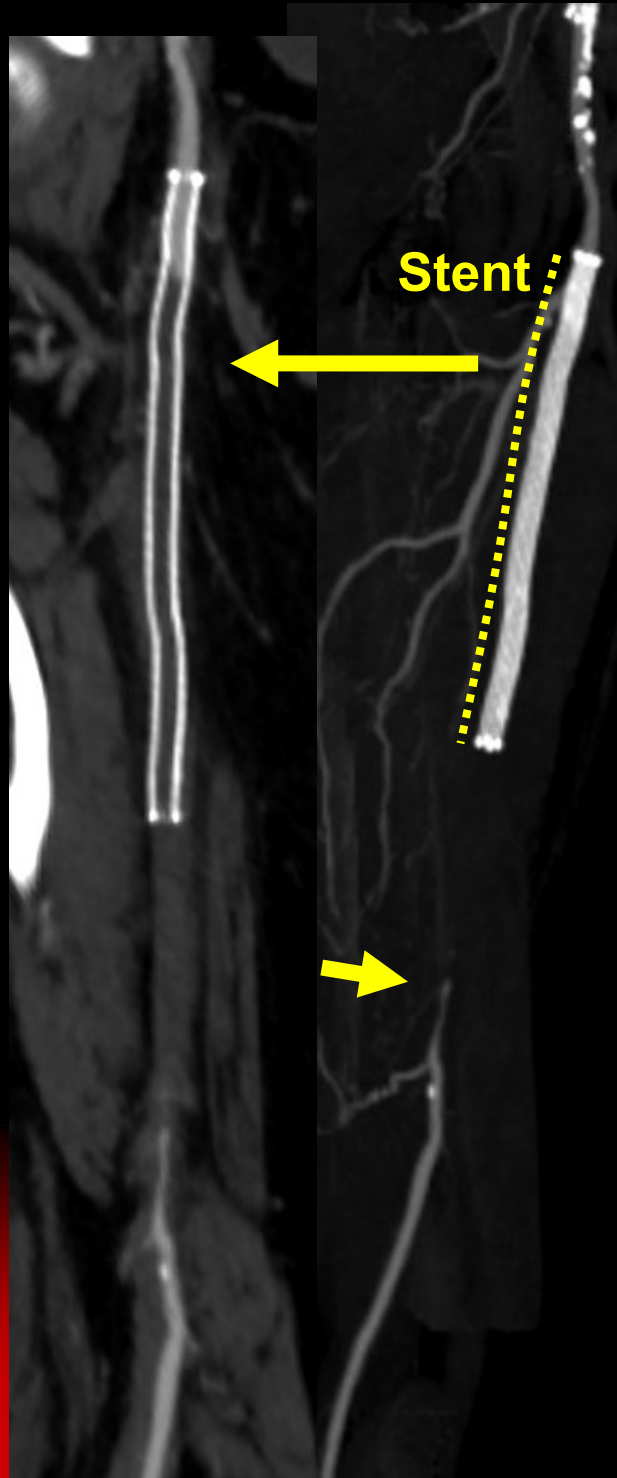
Risk Factor:

**HT**

eGFR: **74.8**

Latest CT Findings: **2023.11**

Rt: **SFA 100%**





**Case 11**      **80's female**

**Target Lesion: Lt. SFA CTO**

**Diagnosis: CLTI**  
**ABI: R=0.56, L=0.61**  
**Rutherford: 5**

**Prior intervention:**  
**2023.10 EVT Stent (Bi, CIA-EIA)**  
**2023.11 EVT DCB (Rt. SFA)**

**Risk Factor:**  
**DM, HT**

**eGFR: 59.9**

**Latest CT Findings: 2023.10**  
**Rt: SFA 90% → 25-50% (DCB)**  
**CIA 100% → 0% (stent)**  
**Lt : SFA 100%**  
**CIA 90% → 0% (stent)**

