

# CPAC 2021

Complex Peripheral Angioplasty Conference

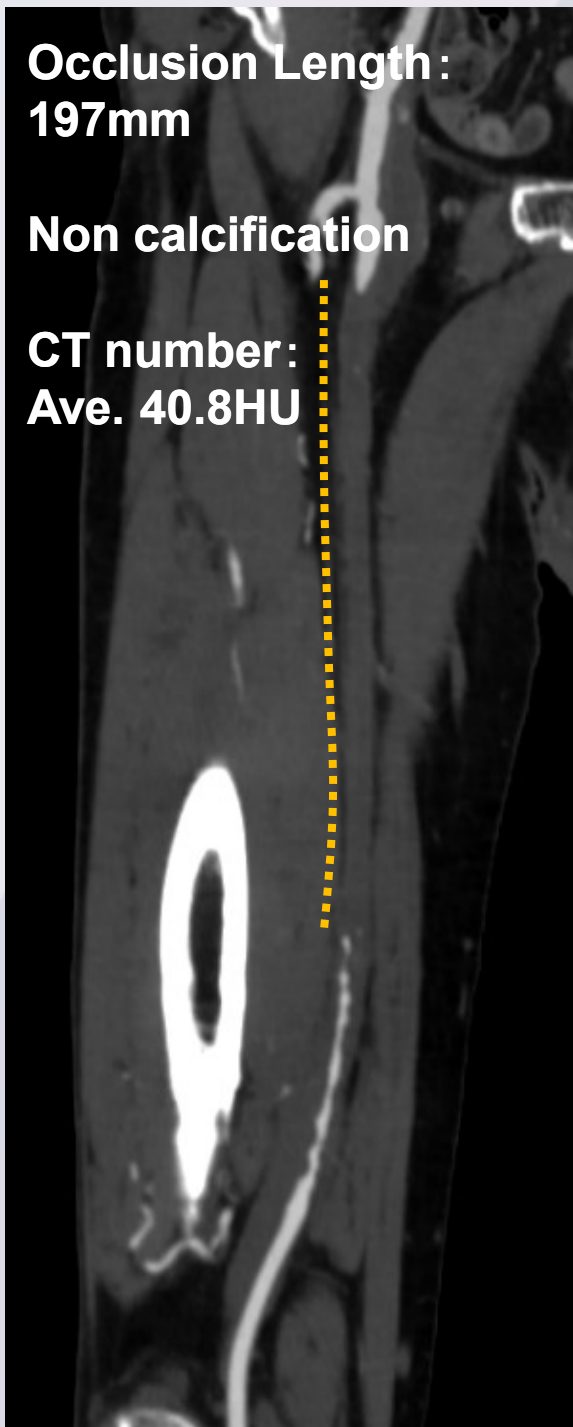
原点回帰 ～真へのこだわり～

## 症例集



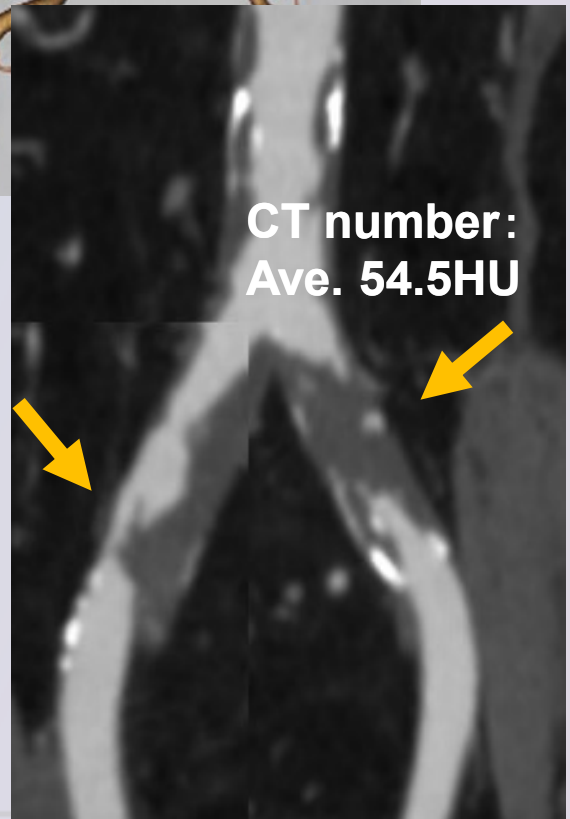
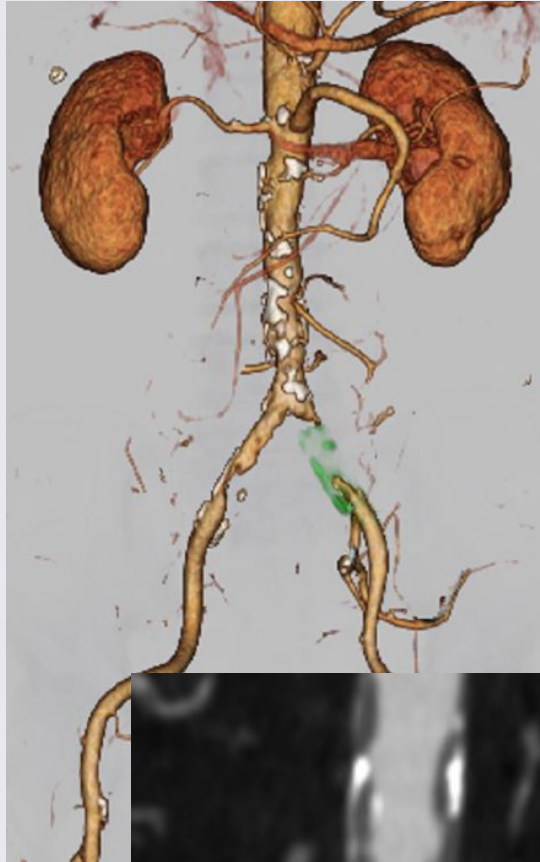**【CASE 1】 80's male****Target Lesion: Rt. SFA CTO (re-occlusion)**

- Diagnosis: PAD, AP
- ABI: R=0.52, L=0.75
- Fontaine: II
- Rutherford: I 2
  
- Prior intervention:  
Oct. 2018 EVT DCB  
(Rt. SFA CTO)
  
- Risk Factor:  
Dyslipidemia, FH
  
- eGFR: 68.7
  
- CT Findings: Oct. 2021  
Rt : SFA 100%, ATA 100%  
Lt : CFA 50%, ATA 100%



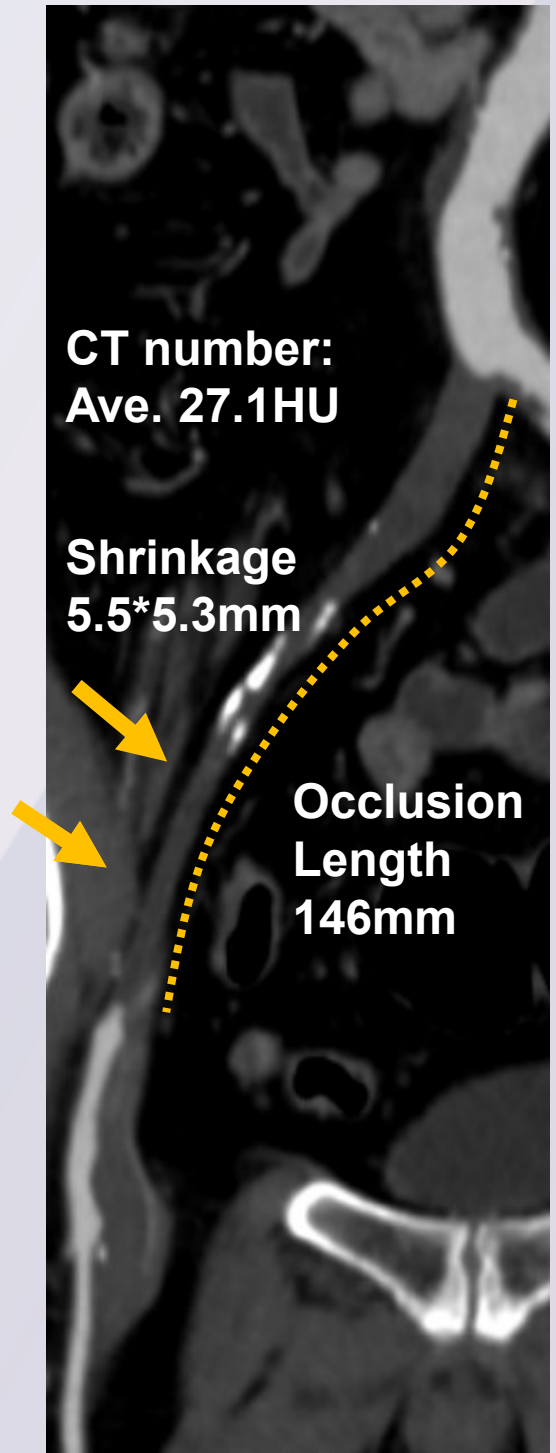
**【CASE 2】 70's male****Target Lesion: Bi. CIA (Lt. CIA CTO)**

- Diagnosis: PAD
- ABI: R=0.78, L=0.50
- Fontaine: II
- Rutherford: I 2
- Prior intervention: none
- Risk Factor: DM, Dyslipidemia
- eGFR: 54.8
- CT Findings: Oct. 2020  
Rt : CIA 90%, CFA 50-75%  
Lt : CIA 100%



**【CASE 3】 70's male****Target Lesion: Rt. CIA-EIA CTO**

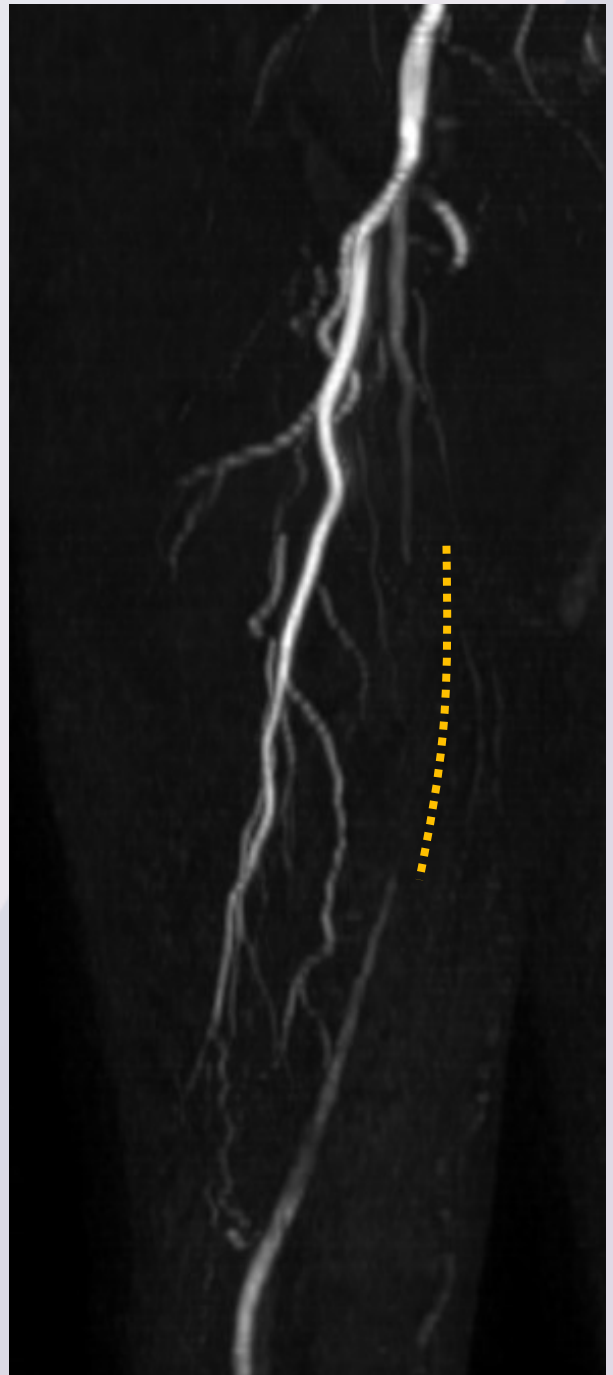
- Diagnosis: PAD, Post PCI
- ABI: R=0.46, L=0.75
- Fontaine: II
- Rutherford: I 3
  
- Prior intervention:  
Jun. 2017 PCI (DES) ,  
other hospital
  
- Risk Factor: DM, HT
  
- eGFR: 61.3
  
- CT Findings: Nov. 2021  
Rt : CIA-EIA 100%



## 【CASE 4】 80's male

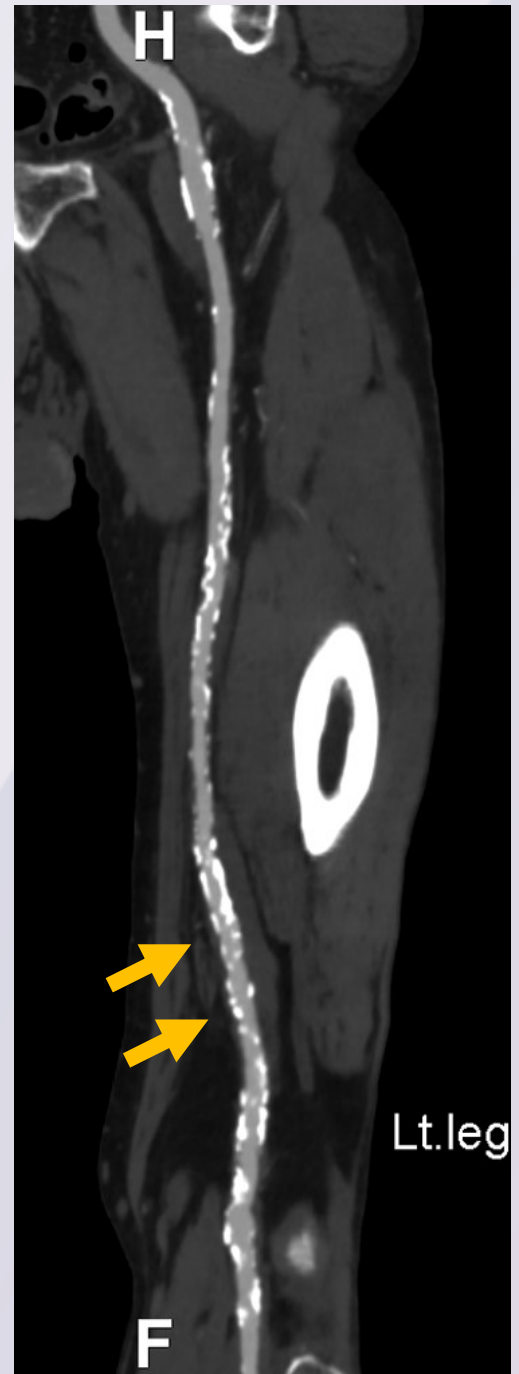### Target Lesion: Rt. SFA CTO

- Diagnosis:  
PAD, Post EVAR, CKD
- ABI: R=0.64, L=0.61
- Fontaine: II
- Rutherford: I 2
  
- Prior intervention:  
Nov. 2021 EVAR (AAA)
  
- Risk Factor:  
Dyslipidemia, HT,  
Past smoking
  
- eGFR: 34.2
  
- MRA Findings: Oct. 2021  
Rt : SFA 100%, ATA 100%  
Lt : SFA 90%, ATA 100%  
Bi EIA un-evaluatable  
(progressive  
saturation effect)



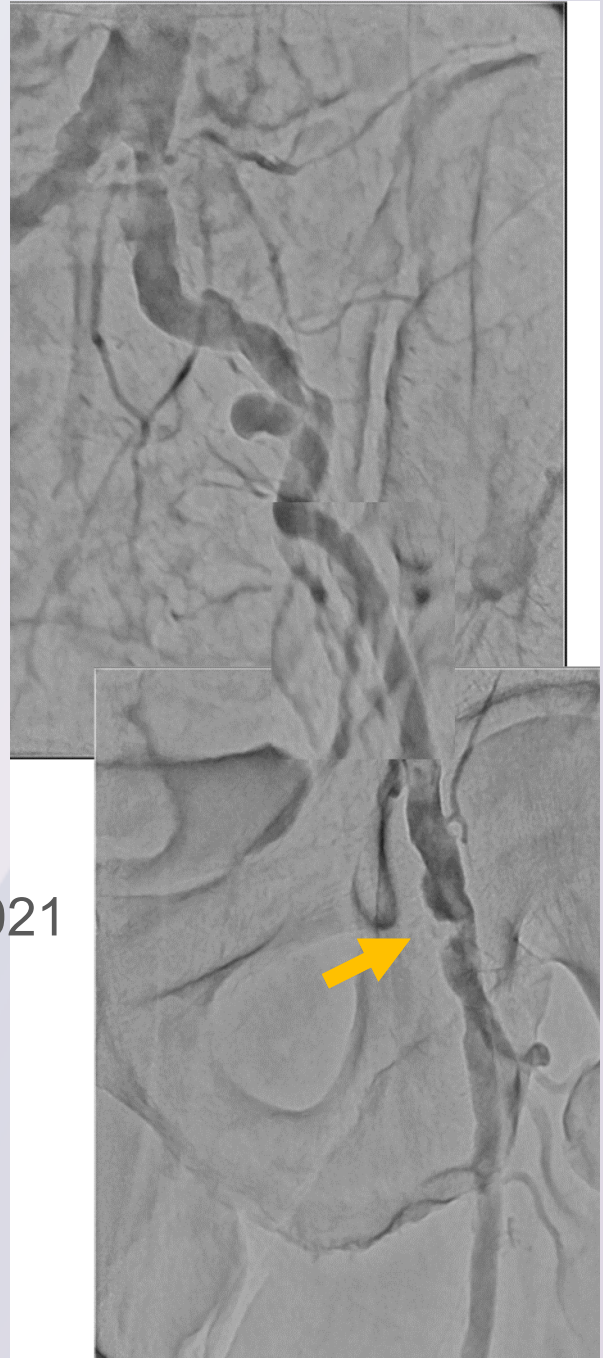**【CASE 5】 70's male****Target Lesion: Lt. SFA calc**

- Diagnosis: PAD
- ABI: R=0.93, L=0.69
- Fontaine: II
- Rutherford: I 2
- Prior intervention:  
Oct. 2020 EVT Stent (Rt. SFA)
- Risk Factor: DM, Smoking
- eGFR: 84.1
- CT Findings: Nov. 2021  
Rt : SFA ISR (-)  
ATA 100%, PTA 100%  
Lt : SFA 90%  
ATA 100%, PTA 100%



**【CASE 6】 70's male****Target Lesion: Lt. CFA severe calcification**

- Diagnosis: PAD, AP
- ABI: R=0.93, L=0.79
- Fontaine: II
- Rutherford: I 2
- Prior intervention:  
Sep. 2021 TAME (Sciatica)
- Risk Factor:  
DM, HT, Dyslipidemia,  
Smoking
- eGFR: 52.8
- Angiography Findings: Nov. 2021  
Rt : CIA 50%, CFA 90%,  
Lt : CIA 50-75%, CFA 90%  
PTA 100%



# 【CASE 6】 70's male

## Target Lesion: Lt. CFA severe calcification

MRA

